Botulinum Toxin 159

Nagasai C. Adusumilli, Elizabeth Tanzi, Alastair Carruthers, Jean Carruthers and Ada Regina Trindade de Almeida

Chapter Contents

Properties of Botulinum Toxins 2705
Cosmetic Use of Botulinum Toxin Type A 2706
Medical Uses of Botulinum Toxin Type A 2714
Complications 2715
Safety 2716

Synonyms: ■ Botulinum toxin type A, botulinum A exotoxin, BoNT-A; onabotulinumtoxinA – BOTOX®/BOTOX® Cosmetic; abobotulinumtoxinA – Dysport®, Azzalure®; incobotulinumtoxinA – Xeomin®/Bocouture®; prabotulinumtoxinA-xvfs – Jeuveau®; daxibotulinumtoxinA-lanm – DAXXIFY®
■ Botulinum toxin type B, BoNT-B; rimabotulinumtoxinB – MYOBLOC®

Key features

- Botulinum toxin (BoNT) causes chemodenervation of muscles by blocking acetylcholine release
- BoNT is also capable of inhibiting the release of other neurotransmitters, such as substance P, noradrenaline, calcitonin gene-related peptide, and glutamate from a variety of synaptosomal and neuronal systems
- Injections of BoNT type A (BoNT-A) that weaken or relax muscles can smooth hyperfunctional lines and change the contour of the face and neck
- Adjunctive use of BoNT-A with soft-tissue augmentation or laser resurfacing is beneficial, particularly in active regions such as the perioral and periocular areas
- The cosmetic effects of BoNT-A typically last months and may increase with subsequent injections
- In addition to its effect on musculature, BoNT-A successfully denervates sweat glands, serving as an effective alternative treatment for hyperhidrosis, and it can also improve the pain, swelling, and discoloration associated with Raynaud phenomenon
- Complications (e.g. eyelid ptosis) are generally caused by diffusion of the toxin to non-targeted muscles and can be minimized by using concentrated doses and careful technique

INTRODUCTION

Botulinum toxin (BoNT) injections are commonly used to improve facial aesthetics by smoothing hyperdynamic rhytides of the face and neck. In recent years, the use of BoNT has evolved to reflect a more three-dimensional approach to facial rejuvenation, often in combination with soft-tissue augmentation or other restorative procedures. Moreover, a better understanding of its mechanism of action has led to innovative indications across a number of therapeutic fields.

PROPERTIES OF BOTULINUM TOXINS

Various strains of the bacterium *Clostridium botulinum* produce seven distinct serotypes of BoNT that affect neural function: A, B, C1, D, E, F and G[1]. Although all serotypes produce chemodenervation and atrophy of skeletal muscles by blocking acetylcholine release from motor neurons at the neuromuscular junction (Fig. 159.1), they differ with regard to cellular mechanism of action and clinical profile.

Formulations

BoNT type A (BoNT-A), the first serotype developed for use in humans, is available in seven formulations worldwide (Table 159.1). Five have been approved by the U.S. Food and Drug Administration (FDA) for the treatment of glabellar rhytides and have been assigned specific drug names to avoid confusion and reduce the potential for dosing errors: onabotulinumtoxinA (onaA; BOTOX®/BOTOX® Cosmetic), abobotulinumtoxinA (aboA; Dysport®, Azzalure®), incobotulinumtoxinA (incoA; Xeomin®/Bocouture®), prabotulinumtoxinA-xvfs (praboA; Jeuveau®), and daxibotulinumtoxinA-lanm (DAXI; DAXXIFY®). Outside of North America, BoNT-A formulations include Prosigne® and Neuronox®. One formulation of BoNT type B (BoNT-B; rimabotulinumtoxinB (rimaB; MYOBLOC®/NeuroBloc®) is also available in North America (see Table 159.1). All preparations of BoNT differ in terms of purification procedures, potency, and clinical effect and may not be used interchangeably.

Clinical Differences

Clinical differences between onaA and aboA have been debated, in particular the possibility of greater diffusion and migration by aboA[2–4]. However, digital image correlation at various time points utilizing speckle-tracking photogrammetry demonstrated no significant differences between aboA and onaA in the reduction of dynamic glabellar rhytides[5]. Similar efficacy for onaA and aboA has also been observed for non-cosmetic indications, such as facial synkinesis[6]. While suggested dosing ratios have ranged from 1 : 2 to 1 : 4 (onaA : aboA), a dosing ratio of 1 : 2.5 has been shown to increase the field of anhidrotic effect[2], and a higher dose ratio of 1 : 3 has been reported to result in greater longevity[3,7,8], as well as a faster onset of action[8]. Although no clear consensus on a conversion factor between products has been reached, current guidelines recommend a dose ratio of 1 : 2.5 or less than 1 : 3[2,9].

The first BoNT formulation without complexing proteins, incoA, has been shown to be as safe and effective as onaA for the treatment of glabellar rhytides, with a rapid onset of effect and duration of effect of up to 5 months or more[10–12]. In contrast to aboA (see above), incoA has similar dosing to onaA. Researchers had initially speculated that complexing proteins would limit diffusion of the active neurotoxin within the target muscle[13], but human and animal studies have suggested otherwise[2,14]. For example, Kerscher and colleagues found no difference in the size of the anhidrotic area after injection with incoA or onaA[2].

In a multicenter, randomized, double-blind, controlled clinical trial that enrolled 540 patients with moderate to severe glabellar rhytides, a single treatment with praboA (20 U) was found to be as safe and effective as onaA; no serious side effects were observed with this more recently approved formulation of BoNT-A[15]. One comparison study of the effectiveness of rimaB versus onaA reported similar findings[16]. Of note, rimaB was FDA-approved in 2000 for cervical dystonia but is used off-label to treat facial rhytides.

When used for the treatment of hyperkinetic lines in the face, there are several key differences between rimaB and onaA: rimaB has a more rapid onset of action but a shorter duration of effect, diffuses more widely, and is associated with greater pain and other side effects when compared to onaA[17]. That said, one study which examined seven doses of rimaB found all to be safe and effective for the treatment of hyperfunctional rhytides, with a dose-related duration of effect[18].

Downloaded for Anonymous User (n/a) at Egyptian Knowledge Bank from ClinicalKey.com by Elsevier on March 10, 2024. For personal use only. No other uses without permission. Copyright ©2024. Elsevier Inc. All rights reserved.

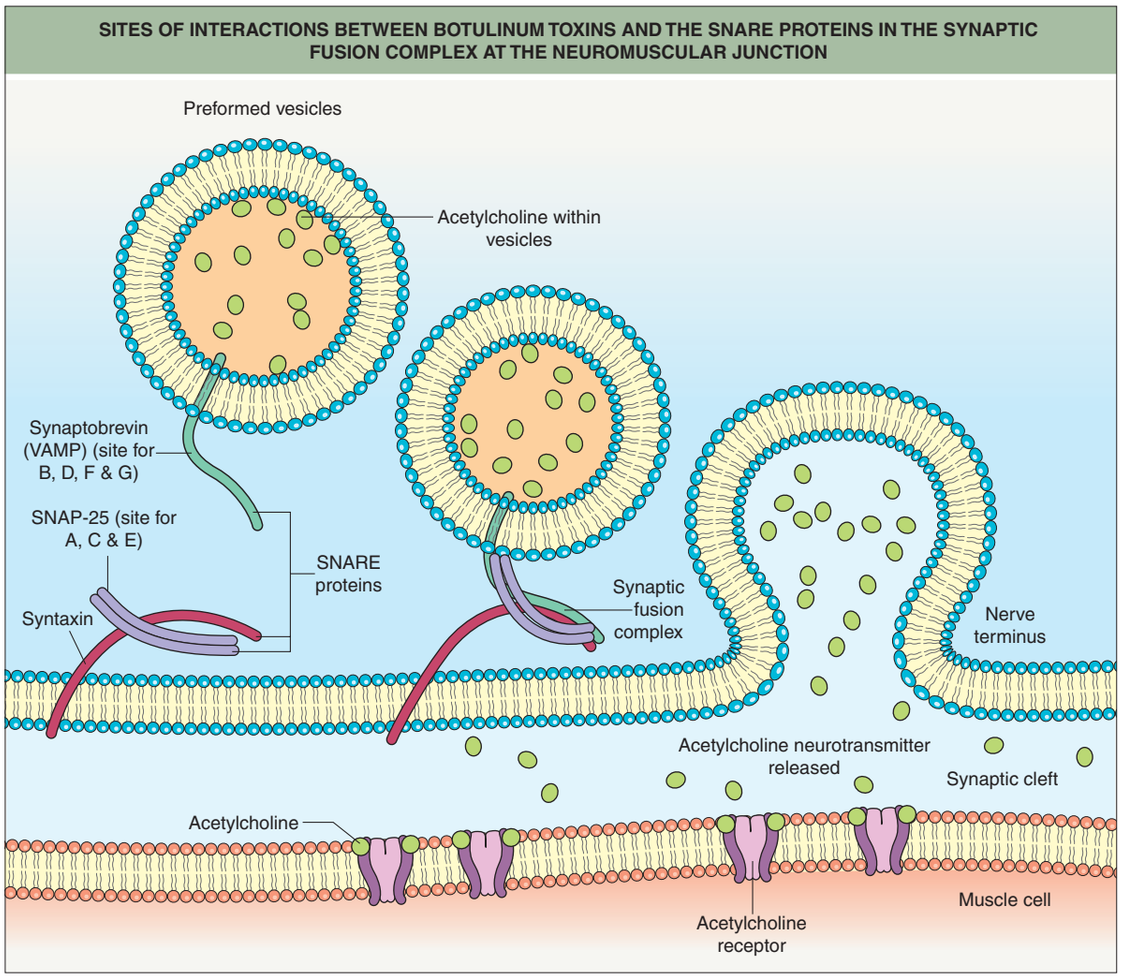

Fig. 159.1 Sites of interactions between botulinum toxins and the SNARE proteins in the synaptic fusion complex at the neuromuscular junction. Botulinum toxins A, C, and E catalyze the cleavage of the SNAP-25 protein. Botulinum toxins B, D, F, and G catalyze the cleavage of synaptobrevin (or the vesicle-associated membrane protein, VAMP). *Adapted from Rohrer TE, Beer K. Background to botulinum toxin. In: Carruthers A, Carruthers J (eds). Botulinum Toxin. Philadelphia: Saunders, 2005.*

Topical BoNT-A

Percutaneous delivery of topical BoNT has been limited by its inability to cross the stratum corneum. As a result, it has been combined with mechanical, chemical, and thermal techniques in an attempt to enhance percutaneous delivery[19–21]. Despite early promising reports of the treatment of lateral canthal rhytides (Fig. 159.2) and primary axillary hyperhidrosis[22–25] with topical formulations of BoNT-A, to date, no such formulations have been approved by the FDA. For example, in contrast to the effectiveness of injectable daxibotulinumtoxinA[26], topical daxibotulinumtoxinA gel did not meet primary endpoints for efficacy in a phase III trial. Nonetheless, topical BoNT-A remains a potential approach for the treatment of anatomic areas that are difficult to manage or particularly painful to inject.

A Note About Dosing

Most of the published information regarding the cosmetic uses of BoNT pertains to the use of onaA, followed in recent years by aboA and incoA. Data are scarce regarding other formulations of BoNT-A. Since most of our experience pertains to the use of onaA, the following discussion (including units and description of techniques) focuses on this formulation specifically. However, a conversion rate of 1 : 1 U may be considered for all 100-U product vials (incoA, Prosigne®, and Neuronox®) and 1 : 2.5 U for aboA.

COSMETIC USE OF BOTULINUM TOXIN TYPE A

Hyperkinetic lines result from the repeated contraction of muscles perpendicular to the rhytides. Weakening or relaxing these muscles with BoNT-A can smooth horizontal lines on the forehead (from frontalis contraction), vertical lines in the glabellar region between the eyebrows (from corrugator contraction), horizontal creases across the bridge of the nose (from procerus contraction), "crow's feet" and lateral lines along the lower eyelid (from lateral orbicularis oculi contraction), and perioral lines (from orbicularis oris contraction). Deep grooves or folds elsewhere that are exacerbated by muscle activity are also amenable to treatment. Patients 30–50 years of age may be most responsive to BoNT-A, because their rhytides are more likely to be caused by muscle activity rather than by the loss of skin elasticity that occurs with aging.

Injections for aesthetic indications may be given intramuscularly, subcutaneously, or intradermally. We use intradermal injections, especially in the crow's feet area, to minimize bruising. All of the usual precautions prior to any injection should be followed. The area may be chilled with ice before injection to minimize any discomfort in sensitive individuals. Alternatively, a topical anesthetic can be applied 15 to 30 minutes prior to injection to minimize discomfort.

The effects of BoNT-A injections are usually apparent within a day or two and are obvious for 3 or 4 months, although they may last for 6 months or more. In comparison to other BoNT-A formulations, injectable daxibotulinumtoxinA (DAXI) has been reported to have a longer duration of effect on glabellar lines[26]. There is also a tendency for repeated BoNT-A injections to provide more prolonged aesthetic improvement.

Glabellar Frown Lines

Frown lines in the glabellar region are caused by contraction of the corrugator supercilii and orbicularis oculi muscles, which move the brow medially, and the procerus and depressor supercilii muscles, which pull the brow inferiorly. Because the corrugator and procerus are used only to control facial expression, the goal of treatment should be to produce a significant weakening of these muscles. The treatment sites and doses should be individualized because the location, size, and use of the frown muscles vary greatly between individuals. We currently use five injection sites when treating glabellar frown lines and vary the dosage depending on the individual brow (Fig. 159.3; Table 159.2). If the extent of the frown reaches the midpupillary line, additional injection sites may be warranted (Video 159.1) The procedure effectively smooths the glabellar lines at rest and prevents their appearance when the patient attempts to frown, for an average of 3 to 4 months (Fig. 159.4)

Downloaded for Anonymous User (n/a) at Egyptian Knowledge Bank from ClinicalKey.com by Elsevier on March 10, 2024. For personal use only. No other uses without permission. Copyright ©2024. Elsevier Inc. All rights reserved.

CURRENTLY AVAILABLE BOTULINUM TOXIN FORMULATIONS AND CLINICAL USES								
	OnaA	**AboA**	**DAXI**	**IncoA**	**PraboA**	**RimaB**	**BoNT-A**	**BoNT-A**
Trade names®	BOTOX/BOTOX Cosmetic/ Vistabel/ Vistabex	Dysport, Azzalure	DAXXIFY	Xeomin/Bocouture	Jeuveau	MYOBLOC/ NeuroBloc	Prosigne/Lantox/ Redux	Neuronox/ Meditoxin/ Botulift
Manufacturer	Allergan, Inc.	Ipsen Biopharm Ltd/Medicis Pharmaceutical Corp. Galderma	Revance Therapeutics, Inc.	Merz Pharmaceuticals	Evolus, Inc.	Solstice Neurosciences, LLC	Lanzhou Institute of Biological Products	Medytox, Inc.
Active substance	BoNT-A + complex (900 kDa)	BoNT-A + complex (400 kDa)	BoNT-A free of complexing proteins (150kDa)	BoNT-A free of complexing proteins (150 kDa)	BoNT-A free of complexing proteins (900 kDa)	BoNT-B + complex (700 kDa)	BoNT-A + complex (900 kDa)	BoNT-A + complex (940 kDa)
Excipients (per vial)	HSA 500 mcg NaCl 0.9 mg	HSA 125 mcg Lactose 2.5 mg	L-histidine 0.14 mg L-histidine-HCl monohydrate 0.65 mg Polysorbate 20 0.1 mg RTP004 peptide 11.7 mcg Trehalose dihydrate 36 mg	HSA 1000 mcg Sucrose 4.7 mg	HSA 500 mcg NaCl 0.9 mg	HSA 500 mcg NaCl 0.1 M Disodium succinate 0.01 M HCl (to adjust pH) Water for injection	Gelatin 5 mg Dextran 25 mg Sucrose 25 mg	HSA 500 mcg NaCl 0.9 mg
Units per vial	50 or 100	300 or 500	50 or 100	100	100	2500, 5000, or 10 000	50 or 100	100
Indications [*FDA-approved in italics*]	*Glabellar lines*, axillary hyperhidrosis**, chronic migraine, blepharospasm, cervical dystonia*	*Glabellar lines*, cervical dystonia*, blepharospasm	*Glabellar lines*	*Blepharospasm, cervical dystonia*, cosmetic use in some countries	*Glabellar lines**	*Cervical dystonia*	Glabellar lines, hyperhidrosis, blepharospasm, cervical dystonia	Blepharospasm
*Moderate to severe glabellar lines **Severe primary axillary hyperhidrosis								

Table 159.1 Currently available botulinum toxin formulations and clinical uses. At the time of writing, BoNT/A-DP by Croma-Pharma GmbH is in Phase III trials. AboA, abobotulinumtoxinA; DAXI, daxibotulinumtoxinA; HSA, human serum albumin; IncoA, incobotulinumtoxinA; OnaA, onabotulinumtoxinA; PraboA, prabotulinumtoxinA-xvfs; RimaB, rimabotulinumtoxinB.

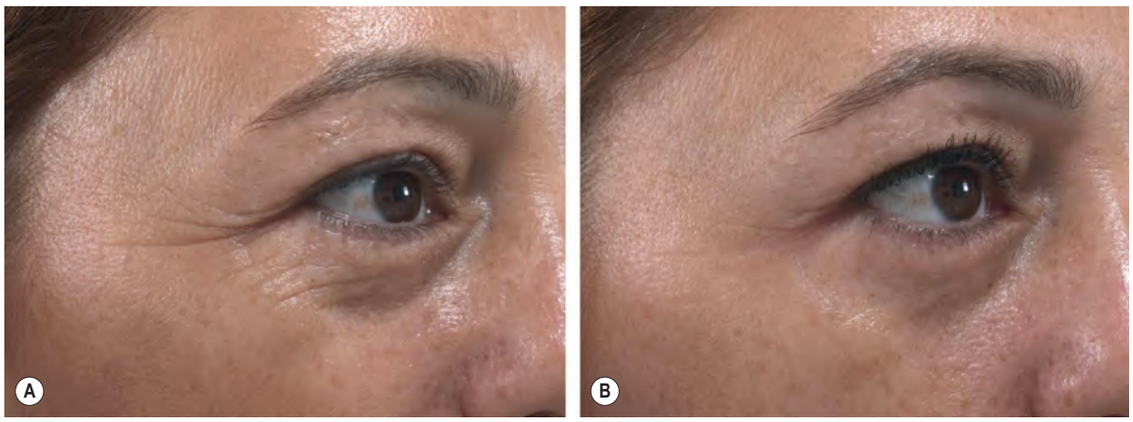

Fig. 159.2 Topical BoNT-A for lateral canthal rhytides (crow's feet). Before (**A**) and after (**B**) treatment.

Crow's Feet

Contraction of the lateral fibers of the orbicularis oculi muscle produces "crow's feet", lines that radiate from the lateral canthus. Since forceful closure of the eyelids requires orbicularis contraction, the goal of treatment is to produce weakening just in the lateral orbital area, rather than a complete paralysis of the muscle. Because the orbicularis oculi is diffusely innervated, multiple injections are required to weaken broad areas of the muscle. Doses and sites vary among clinicians – we evenly distribute the BoNT-A into two to four separate injection sites (Fig. 159.5; see Table 159.2) while others may employ up to seven injection sites (Video 159.2). Results last approximately 3 months (Fig. 159.6).

Horizontal Forehead Lines

Deep horizontal creases in the forehead are produced by the repeated contraction of the frontalis muscle. This large, vertically oriented muscle is the brow elevator; it inserts superiorly into the galea aponeurotica and inferiorly into the skin of the brow. Unfortunately, weakening the

Downloaded for Anonymous User (n/a) at Egyptian Knowledge Bank from ClinicalKey.com by Elsevier on March 10, 2024. For personal use only. No other uses without permission. Copyright ©2024. Elsevier Inc. All rights reserved.

frontalis muscle sufficiently to eliminate hyperkinetic forehead lines can result in undesired brow ptosis or a complete lack of expressiveness. Therefore, it is our practice to divide the BoNT-A amongst multiple sites distributed horizontally across the midforehead (Fig. 159.7; see Table 159.2). The goal of treatment is to only soften, rather than completely eliminate, forehead lines. Ideally, the individual will still be able to elevate the eyebrows, albeit to a lesser extent, after treatment (Fig. 159.8). We believe that the brow depressors should *always* be treated at the same time as the frontalis, and so we employ the technique described in the next section. Effects typically last from 3 to 6 months (Video 159.3).

Brow Lift and Shaping

Brow ptosis often occurs during aging, resulting in an angry, scowling expression. Notably, the shape and height of the eyebrows are

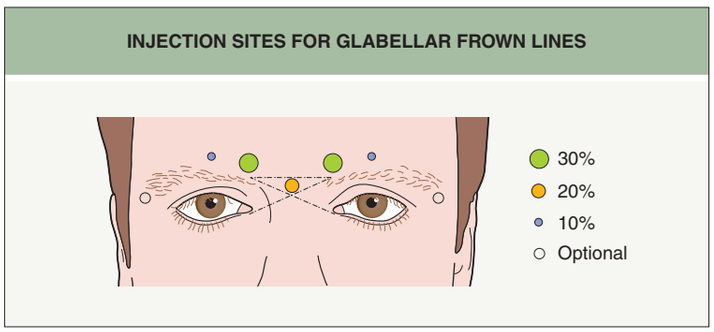

Fig. 159.3 Injection sites for glabellar frown lines. The authors currently use five injection sites when treating glabellar frown lines and vary the dosage depending on the individual brow. The injection in the midpupillary line may be omitted if eyebrow ptosis seems likely or possible. Sometimes, an injection is made above the lateral canthus or into the tail of the eyebrow.

USE OF onaA IN THE UPPER FACE: DOSING AND TECHNIQUES	
Treatment area	**Injection sites and tips**
Glabellar rhytides	• Men: starting dose 60 U, titrate to 100 U; women: starting dose 30 U, titrate to 50 U • 7–10 U (women) or 15–20 U (men) just above the superior bony orbital rim directly above the inner canthus on each side (Fig. 159.3) • 5–10 U into procerus muscle at midline • For horizontal brows: 4–5 U 1 cm above bony supraorbital rim in the midpupillary line* • Sometimes necessary to inject above lateral canthus or into the tail of the eyebrow to improve lateral eyebrow position
Lateral canthal rhytides (crow's feet)	• 12–15 U/side, distributed amongst 2–4 sites (Fig. 159.5) • Inject when patient is *not* smiling to avoid affecting the ipsilateral zygomaticus complex (which can lead to upper lip ptosis) • Inject lateral to the lateral orbital rim; more medial injections can cause lower eyelid droop • Superficial injections (as few as possible) will avoid bruising • Avoid injecting superficial veins
Horizontal forehead rhytides	• 10–15 U amongst multiple sites horizontally across the midforehead, 2–3 cm above the eyebrows (Fig. 159.7) • 5 injection sites for broad foreheads†; 4 injection sites and a slightly lower dose for narrow foreheads
Hypertrophic orbicularis oculi muscle	• Subcutaneous injections of 2–4 U in the midpupillary line, 3 mm below the ciliary margin (Fig. 159.9) • Higher doses can result in keratoconjunctivitis sicca (dry eye)

*Injection site most likely to cause ptosis.
†More than 12 cm between the temporal fusion lines (the slight prominence at the point where the temporalis fascia joins the skull) at the midforehead level.

Table 159.2 Use of onaA in the upper face: dosing and techniques.

Fig. 159.4 Effect of BoNT-A injections for glabellar frown lines. A subject at rest (**A**) and during frowning (**B**). Same subject at rest (**C**) and attempting to frown (**D**) two weeks after BoNT-A treatment.

Downloaded for Anonymous User (n/a) at Egyptian Knowledge Bank from ClinicalKey.com by Elsevier on March 10, 2024. For personal use only. No other uses without permission. Copyright ©2024. Elsevier Inc. All rights reserved.

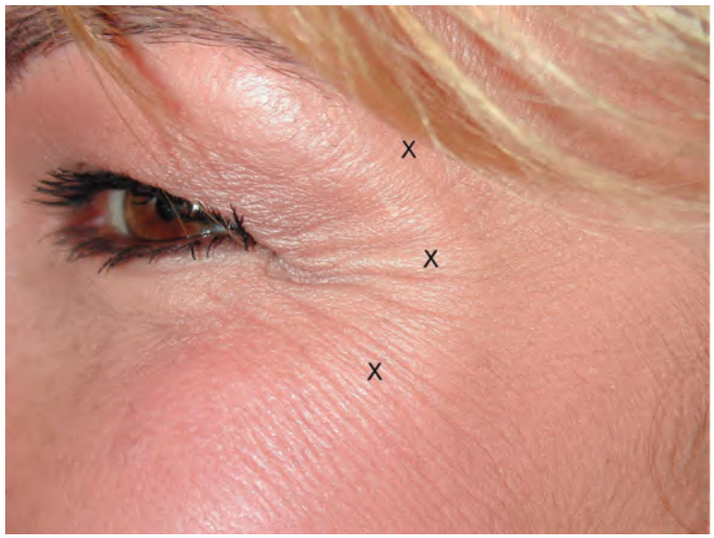

Fig. 159.5 Injection sites for lateral canthal rhytides (crow's feet). The authors inject 12–15 U of onaA per side among two to four injection sites.

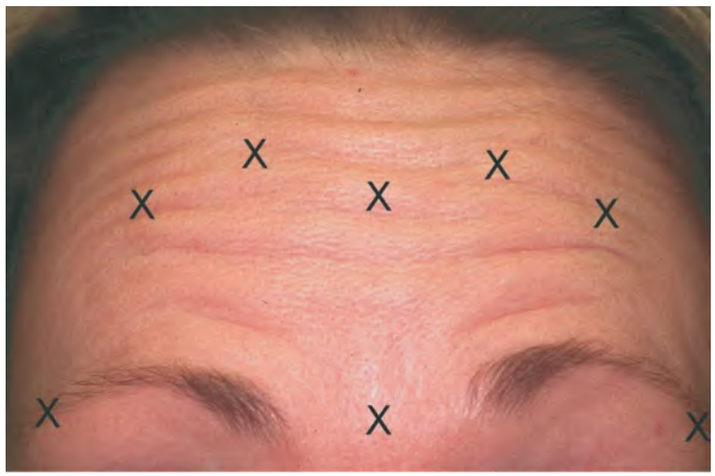

Fig. 159.7 Injection sites for horizontal forehead lines. Injection sites must be kept well above the brow. The lower X's mark the sites of injection of the brow depressors.

Fig. 159.6 Effect of BoNT-A injections for lateral canthal rhytides (crow's feet). Subject before (**A**) and after (**B**) BoNT-A treatment.

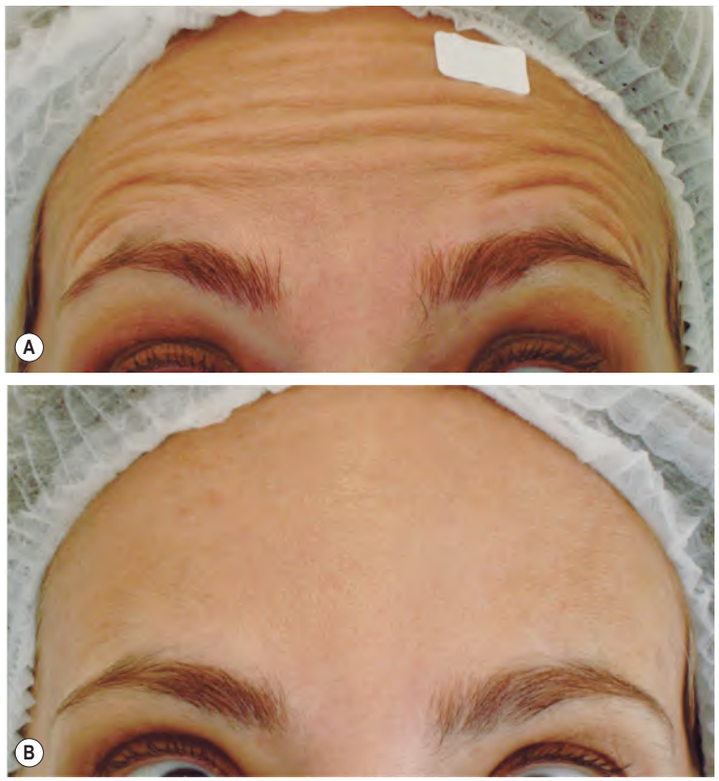

Fig. 159.8 Effect of BoNT-A injections for horizontal forehead lines. The subject elevates the brows before (**A**) and after (**B**) BoNT-A treatment.

determined by the opposing activity of the frontalis muscle, which elevates the brow, and the brow depressors. The medial brow depressors are the corrugator supercilii, the procerus, and the medial portion of the orbicularis oculi; the lateral depressor is the lateral portion of the orbicularis oculi (that is lateral to the temporal fusion line). Although we initially believed that brow lifts were a result of the inactivation of the brow depressors, subsequent research showed that central injections of 20–40 U of onaA into the glabella alone (with the most lateral injection at the midpupillary line) led to a dramatic lateral eyebrow elevation, followed by an entire brow lift that peaked 12 weeks after treatment, while too little (10 U) led to a brief fall in eyebrow position[27]. We now believe that the change in eyebrow position after glabellar injection in women is due to diffusion of the toxin into the lower frontalis muscle, which causes an improved resting tone in the remainder of the muscle and in eyebrow position.

Hypertrophic Orbicularis Oculi

The pretarsal portion of the orbicularis oculi muscle is involved in the blink reflex. Contraction of the pretarsal orbicularis during smiling tends to decrease the size of the palpebral aperture. Hypertrophy of this muscle can give a "jelly roll" appearance to the lower eyelid, enough that some individuals may complain that they look overweight. We have found that injection of 2 U (or occasionally 4 U) of onaA into the lower pretarsal orbicularis (Fig. 159.9) opens the palpebral aperture both at rest and during smiling (Fig. 159.10; see Table 159.2)[28].

Midface Injections

Contraction of the upper nasalis muscle causes fanning rhytides ("bunny lines") at the nasal root (Fig. 159.11). BoNT-A treatment weakens the upper nasalis and dramatically softens these lines. Bunny lines are typically treated in conjunction with the glabellar complex (Table 159.3).

Downloaded for Anonymous User (n/a) at Egyptian Knowledge Bank from ClinicalKey.com by Elsevier on March 10, 2024. For personal use only. No other uses without permission. Copyright ©2024. Elsevier Inc. All rights reserved.

Fig. 159.9 Injection sites for hypertrophic orbicularis oculi muscle. 2–4 U of onaA are injected into the lower pretarsal orbicularis oculi muscle.

Fig. 159.10 Effect of BoNT-A injections for hypertrophic orbicularis oculi muscle. Treatment of the lower pretarsal orbicularis opens the palpebral aperture. Note the position of the lower eyelids in the subject before (**A**) and after (**B**) BoNT-A treatment.

Some individuals repeatedly and embarrassingly dilate their nostrils in social situations. The sides of the columella/septum become visible when the nostrils are prominently flared. Contraction of the nasalis muscle accentuates the nasal flare. Small doses of BoNT-A can produce a satisfactory decrease in involuntary nostril flare in some patients for 3 to 4 months (see Table 159.3).

The nasolabial folds extend from the lateral nasal ala to a point lateral to the external angle of the mouth. Young adults have a shallow indentation, but older individuals who smile excessively or sustain photodamage can develop a permanent, deep crevice. The most common treatments for nasolabial folds have been soft-tissue fillers and laser resurfacing. Although muscle contraction contributes to the appearance of the folds, injecting BoNT-A directly into the area of the fold

Fig. 159.11 Injection sites for bunny lines. 2–4 U of BoNT-A injected in each belly of the upper nasalis, at the lateral bony dorsum of the nose.

USE OF onaA IN THE MIDFACE: DOSING AND TECHNIQUES	
Treatment area	**Injection sites and tips**
Bunny lines	• 2–4 U into the upper nasalis muscle, usually 1 injection/side (Fig. 159.11) • Inject well above nasofacial groove* to avoid lip ptosis (due to relaxing the levator labii superioris muscle) • Injection followed by gentle massage
Repeated nasal flare	• 5–10 U bilaterally into lower nasalis muscle fibers covering the lateral nasal ala • Inject the most active area of contraction
Nasolabial folds	• Select patients only, e.g. those with a naturally shorter cutaneous upper lip • 1 U into each lip elevator complex above the nasofacial groove
Nasal tip droop	• 2–3 U into depressor septi nasi muscle at the base of the columella
*Refers to groove between the nose and cheek.	

Table 159.3 Use of onaA in the midface: dosing and techniques.

is not recommended, because it is likely to result in an asymmetric smile, flaccid cheek and flattening of the midface, along with a vertical lengthening of the cutaneous upper lip, leading to incomplete or disappointing results. However, for some individuals who have a naturally shorter cutaneous upper lip, very small doses of BoNT-A can be beneficial for improving nasolabial folds (see Table 159.3), particularly when the injections are given concurrently with fillers or resurfacing. Because duration of effect of this procedure is relatively long (~6 months), it is important to be very careful in patient selection and to be clear about the potential results of the procedure.

Nasal tip droop is common during aging. Contraction of the depressor septi nasi, a small muscle located at the external base of the nasal septum, pulls the tip of the nose downward. BoNT-A slightly elevates the nasal tip (see Table 159.3). Caution should be taken with individuals who already have a long non-vermilion upper lip, because of an associated risk of lip ptosis.

Vertical Lip Rhytides (Perioral Lines)

During aging, the mouth undergoes characteristic changes: the lateral portions of the lips recede to produce a "rosebud mouth"; the vertical distance between the columella and the vermilion border of the upper lip increases, and the substance of the vermilion lip rolls inside, producing the thin and disappointed lips characteristic of old age. The cutaneous upper lip lengthens, and dense vertical perioral rhytides appear. These vertical lines are commonly referred to as "smokers' lines" but they can have other causes, such as heredity, photodamage, or activities

Downloaded for Anonymous User (n/a) at Egyptian Knowledge Bank from ClinicalKey.com by Elsevier on March 10, 2024. For personal use only. No other uses without permission. Copyright ©2024. Elsevier Inc. All rights reserved.

such as playing a musical instrument that require pursing of the lips. Radial upper lip rhytides are exaggerated by the pursestring-like action of the orbicularis oris sphincter muscle of the lip. Multiple fine rhytides of the upper lip can be effectively treated with fillers such as hyaluronic acid or with mid-depth or deeper resurfacing. However, deeper rhytides may be resistant to these treatments.

BoNT-A treatment of the lip sphincter is recommended only for deep lines. Small doses that produce localized microparesis of the orbicularis oris can dramatically reduce radial lip lines and improve the appearance of the lips (Table 159.4). To maintain competence of the mouth, it is important to be conservative with dosing, and superficial injections are recommended over deep injections (Fig. 159.12) (Video 159.4). Even with conservative dosing, however, BoNT-A treatment of perioral lines may result in lip sphincter weakening that subtly affects mouth function. This procedure may not be desirable for musicians who play wind instruments and professional singers or speakers. Some patients have difficulty with lip proprioception after treatment, but eating, drinking and singing are typically not affected. BoNT-A injections for radial lip lines may be particularly useful in combination with perioral laser or electrosurgical resurfacing or in combination with a soft-tissue-augmenting agent such as hyaluronic acid (Fig. 159.13).

USE OF onaA IN THE LOWER FACE AND NECK: DOSING AND TECHNIQUES	
Treatment area	**Injection sites and tips**
Perioral rhytides	• 4 U/lip (2 U/lip quadrant); typically 1 U/vertical lip line (Fig. 159.12) • Inject into area of muscle contraction adjacent to the creases at the vermilion border on either side of Cupid's bow • Avoid injecting lip corners (can lead to drooping of the lateral lip and drooling) as well as the midline (can lead to flattening of Cupid's bow)
Upper gum show	• 1–2 U into levator labii superioris alaeque nasi muscle (on each side of the bony nasal prominence) • Younger patients
Mouth frown	• 2–3 U into the posterior aspect of the depressor anguli oris (DAO) muscle on each side, close to the mandible (Fig. 159.15) • Additional 3 U into each mentalis muscle insertion • Asking the patient to frown can aid in identifying the DAO muscle • Not recommended for singers or musicians
Marionette lines	• 2–5 U into each DAO muscle immediately above the angle of the mandible and 1 cm lateral to the lateral oral commissure; amount injected depends upon size of the muscle • Injection must be lateral and low, at the junction of the depressor and the superior margin of the mandible • An injection too medial or too high can cause ipsilateral weakness of the depressor labii inferioris muscle and flattening of the lower lip contour when the mouth attempts to form an "O"; an injection too high may compromise sphincter function and cause mouth incompetence
Mental crease	• 3–5 U/mentalis muscle band
Peau d'orange chin	• 5–10 U into mentalis muscle at the most distal point from the orbicularis oris muscle (i.e. the prominence of the chin; Fig. 159.18)
Masseteric hypertrophy	• 20–35 U into each masseter muscle
Platysmal bands	• 5 U into contracted platysma muscle; 3 sites at 1–1.5 cm intervals for a total of 15 U/band (Fig. 159.20A) • Single treatment typically involves 2 bands and a total dose of 30 U into the neck • Recommended only for patients who have obvious platysmal bands, good cervical skin elasticity, and minimal submental fat accumulation

Table 159.4 Use of onaA in the lower face and neck: dosing and techniques.

Facial Asymmetry: Functional Muscle Imbalance

Injections of BoNT-A can be used to correct facial asymmetry resulting from facial nerve palsies, dystonias, surgery, or trauma[29]. In cases of hemiparesis, BoNT-A is used to decrease muscle activity on the unaffected side; for hyperkinesia, the affected muscles are treated.

Midfacial asymmetry may have bony tissue, soft tissue, innervational or muscular causes. BoNT-A treatment can be invaluable for patients with facial asymmetry caused by neuromuscular abnormalities. In hemifacial spasm, repeated clonic and tonic facial movements draw the facial midline over toward the hyperfunctional side. BoNT-A treatment of the hyperfunctional zygomaticus, risorius and masseter muscles allows the face to be centered at rest. Hypofunctional asymmetry, such as that seen in Bell palsy due to unilateral seventh nerve dysfunction, can be relieved by small doses of BoNT-A injected into muscles on the normally functioning side. Only 1–2 U of onaA into the zygomaticus, risorius, and orbicularis oris muscles and 5–10 U into the masseter muscle are needed to restore facial symmetry (Fig. 159.14).

For patients with asymmetric jaw movement, intraoral injection of 10–15 U of onaA into the internal pterygoid on the hyperfunctional side can relax the jaw and relieve discomfort. Unilateral surgical or traumatic injury of the orbicularis oris or the risorius muscle can cause the mouth to be pulled off-center by the unopposed actions of the partner muscles on the uninjured side. Chemodenervation of the risorius immediately lateral to the corner of the mouth on the uninjured side re-centers the mouth when the face is at rest. Similarly, facial asymmetry is evident in individuals with congenital or acquired unilateral weakness of the depressor anguli oris (DAO) muscle, who are unable to depress the corner of one side of the mouth. In these cases as well, BoNT-A treatment of the partner muscle restores aesthetic balance.

Mouth Frown

The frowning expression created when the lateral corners of the mouth are permanently angled downward can create an impression of disapproval and unpleasantness. The DAO muscle pulls down the corner of the mouth in opposition to the zygomaticus major and minor muscles. BoNT-A can be used to weaken the DAO and reset muscular balance (Fig. 159.15), allowing the zygomaticus to elevate the corners of the mouth and return them to a horizontal position (Fig. 159.16). The effects of this procedure may be potentiated with repeated treatment.

It is always important to be cautious when injecting toxin close to the mouth. A misplaced injection could result in complications, including a flaccid cheek, incompetent mouth, or asymmetric smile. This treatment is not recommended for singers or musicians, or for patients who use their perioral muscle with intensity. With this procedure, as for others in the perioral area, the most pleasing results may be obtained with BoNT-A injections in combination with laser resurfacing.

Melomental Folds (Marionette Lines)

Melomental folds ("drool grooves" or marionette lines) extending from the down-turned corner of the mouth to the lateral mentum

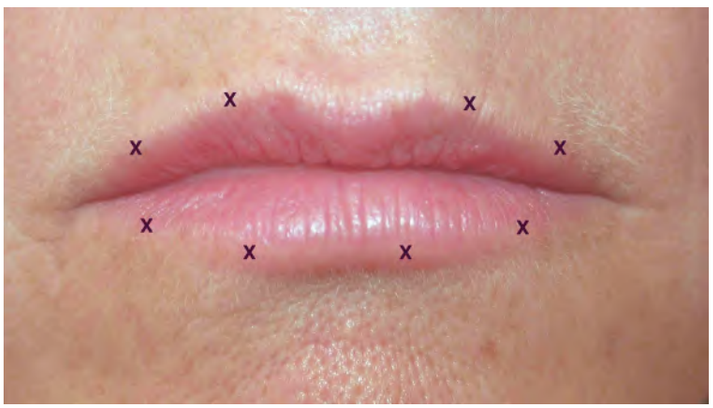

Fig. 159.12 Injection sites for perioral rhytides. The authors typically inject 1 U of onaA per lip line.

Downloaded for Anonymous User (n/a) at Egyptian Knowledge Bank from ClinicalKey.com by Elsevier on March 10, 2024. For personal use only. No other uses without permission. Copyright ©2024. Elsevier Inc. All rights reserved.

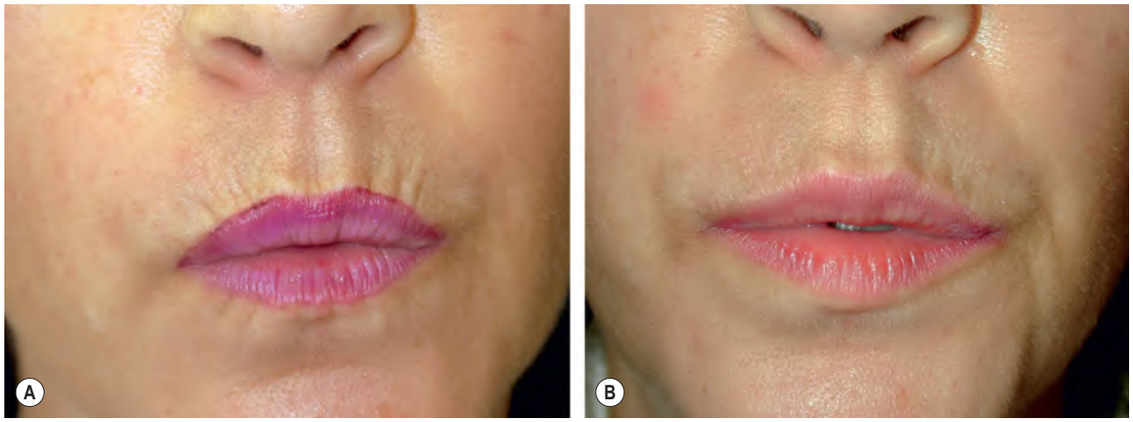

Fig. 159.13 Effect of BoNT-A injections for radial lip lines. This treatment is particularly efficacious when used in combination with a soft-tissue-augmenting agent such as hyaluronic acid. Before (**A**) and after (**B**) BoNT-A treatment.

Fig. 159.14 Left-sided Bell palsy. Before (**A**) and after (**B**) BoNT-A treatment of the right side, with improvement in asymmetry. The authors typically inject 1–2 U of onaA into the zygomaticus, risorius, and orbicularis oris muscles and 5–10 U into the masseter muscle.

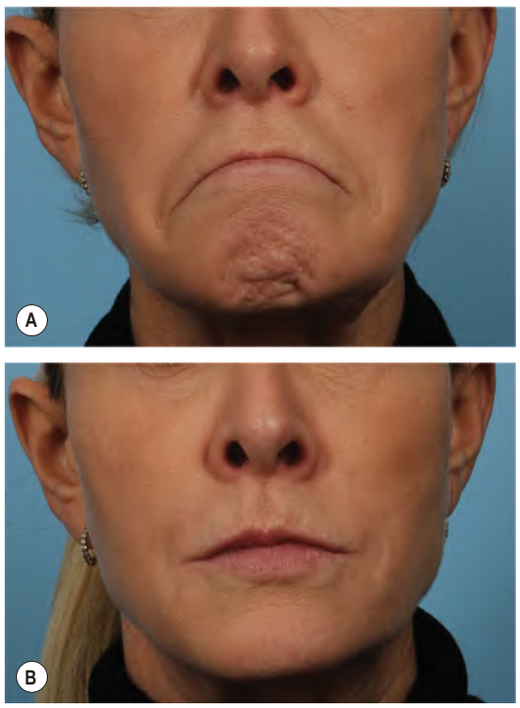

Fig. 159.16 Effect of BoNT-A injections for mouth frown. Before (**A**) and after (**B**) BoNT-A treatment. The authors typically inject 2–3 U of onaA into the posterior aspect of the depressor anguli oris muscle and 3 U into each insertion of the mentalis muscle.

Fig. 159.15 Injection sites for mouth frown.

involuntarily produce a sad expression and give the appearance of advancing age. Because contraction of the DAO muscle exacerbates the melomental folds, BoNT-A treatment is a useful adjunct to soft-tissue augmentation (see Table 159.4). Best results in this area are obtained with combined therapy as BoNT-A treatment prevents the repeated molding and contortion of the implant, enhancing and extending the duration of the soft-tissue augmentation. When performing a comprehensive approach to the entire aging face, BoNT-A treatment of the DAO muscle is often included (Video 159.5)

Mental Crease

The convexity between the lower lip and the prominence of the chin is called the mental crease. Contraction of the mentalis muscle can produce a deep groove in this region. This area is closely tethered to the bony mentum (chin), and soft-tissue augmentation of the mental crease is often unsuccessful because the filling agent visibly beads. BoNT-A injections at the level of the crease may also give unsatisfactory results because the orbicularis oris is weakened, sometimes resulting in an incompetent mouth. However, injection of the mentalis muscle gives a satisfactory softening of the crease while avoiding complications from weakening of the orbicularis oris (see Table 159.4). Injections into the mentalis are especially valuable in individuals who have had previous trauma or surgery to this area (Fig. 159.17).

Peau d'Orange (Apple Dumpling) Chin

An "orange peel" appearance of the chin during aging results from the loss of dermal collagen and subcutaneous fat at the mentum.

Downloaded for Anonymous User (n/a) at Egyptian Knowledge Bank from ClinicalKey.com by Elsevier on March 10, 2024. For personal use only. No other uses without permission. Copyright ©2024. Elsevier Inc. All rights reserved.

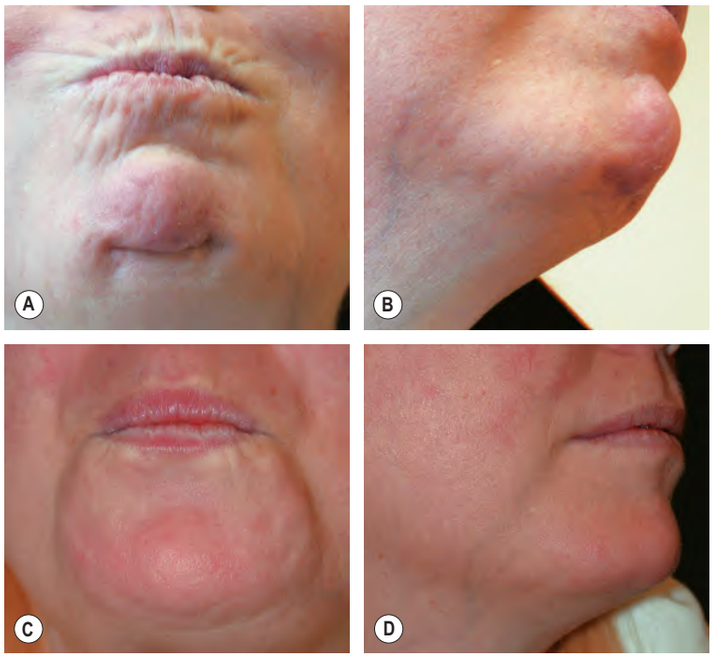

Fig. 159.17 Effect of BoNT-A injections on a mental crease. Subject puckers before (**A, B**) and two weeks after (**C, D**) chemodenervation of a traumatically damaged mentalis muscle with BoNT-A.

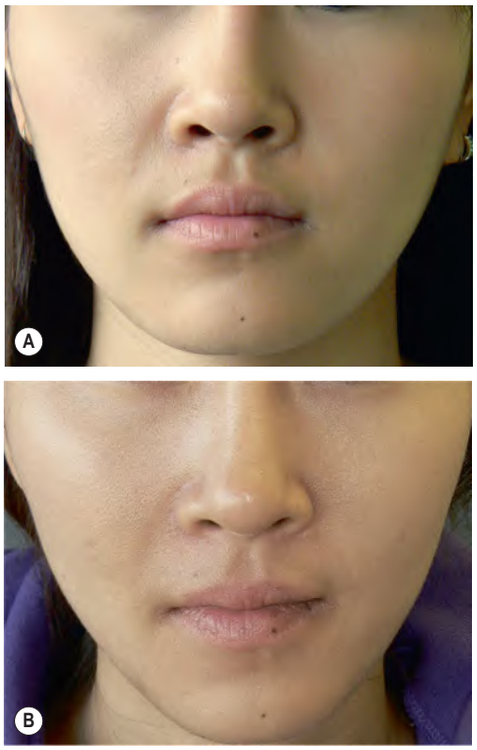

Fig. 159.19 Effect of BoNT-A injections on masseteric hypertrophy. Subject before (**A**) and after (**B**) BoNT-A treatment. The authors inject 20–35 U onaA into each masseter muscle.

Fig. 159.18 Injection sites for a *peau d'orange* chin. The authors inject 5–10 U of onaA into the mentalis muscle at these sites.

The appearance worsens when the mentalis and depressor labii inferioris muscles are used together with the orbicularis oris muscle during mastication or speech. *Peau d'orange* chin is frequently seen asymmetrically during and after recovery from unilateral facial paresis (Bell palsy). Previous treatment options have included soft-tissue augmentation to fill in the tissue gaps and ablative and non-ablative laser resurfacing. Depending upon the patient's aesthetic need for chin augmentation, BoNT-A and soft-tissue augmentation can be used together, or BoNT-A can be used alone to improve the appearance of the chin (Fig. 159.18; see Table 159.4) (Video 159.6). Following treatment, the chin is massaged to facilitate diffusion of the toxin.

Masseteric Hypertrophy

A number of studies have observed a reduction of muscle thickness in Asian and White[30] patients with masseteric hypertrophy who were treated with BoNT-A. Reductions in muscle bulk ranged from 20% to 50% and lasted from 3 to 6 months, depending upon the doses used. Effective sculpting of the jawline can be achieved (Fig. 159.19; see Table 159.4). When investigated in a White versus East Asian population, smaller doses were required for aesthetic improvement in the former versus the latter, and patients experienced a 6- to 7-month improvement in symptoms of bruxism[30].

Platysmal Bands

Platysmal bands are formed when the anterior fibers of the platysma separate into two discrete vertical bands. The bands often tighten and become more visible when the neck is animated, as when the patient speaks, exercises, or plays a musical instrument. The emergence of platysmal bands during aging is often accompanied by other senescent changes, including loss of cervical skin elasticity and accumulation of submental fat. BoNT chemodenervation of the anterior part of the platysma muscle can soften the platysmal bands (Fig. 159.20) and produce a gentle anterior neck lift. However, in aging necks with jowl formation and bone resorption, BoNT-A treatment of the platysma may emphasize, rather than soften, the muscle cords. Thus, chemodenervation of the platysma is recommended only for patients who have obvious platysmal bands, good cervical skin elasticity, and minimal submental fat accumulation.

Large doses of BoNT-A must be used cautiously in the neck. The platysma is external to the larynx and the muscles of deglutition and neck flexion. Doses from 75–100 U of onaA can produce weakness in the neck flexors and dysphagia, and we have reported one patient treated with only 60 U in her neck who developed such profound dysphagia that she required a nasogastric tube until she could swallow again[31]. Therefore, we recommend that the physician proceed with caution and inject no more than 30–40 U of onaA spread over multiple sites per cervical treatment session (see Table 159.4).

Adjunctive Use

BoNT-A is beneficial in many patients as adjunctive therapy in order to enhance or prolong the results of other cosmetic procedures. Prior to surgery, BoNT-A treatment to chemodenervate specific muscles can facilitate subsequent manipulation of tissues during the surgery and permit a greater surgical correction or a better concealment of the surgical incision. BoNT-A can also be used to reduce tension exerted on a wound or surgical incision by the underlying muscles, thereby promoting better healing with less scar formation[32].

Combination treatment with lasers, light-based modalities, and soft-tissue augmentation offers a synergistic approach to the treatment of facial aging. BoNT-A in conjunction with ablative resurfacing leads to optimal improvement of dynamic rhytides, with superior and longer-lasting outcomes[33]. Regular postoperative injections, given every 6 to 12 months, prolong the effects of resurfacing, and many clinicians

Downloaded for Anonymous User (n/a) at Egyptian Knowledge Bank from ClinicalKey.com by Elsevier on March 10, 2024. For personal use only. No other uses without permission. Copyright ©2024. Elsevier Inc. All rights reserved.

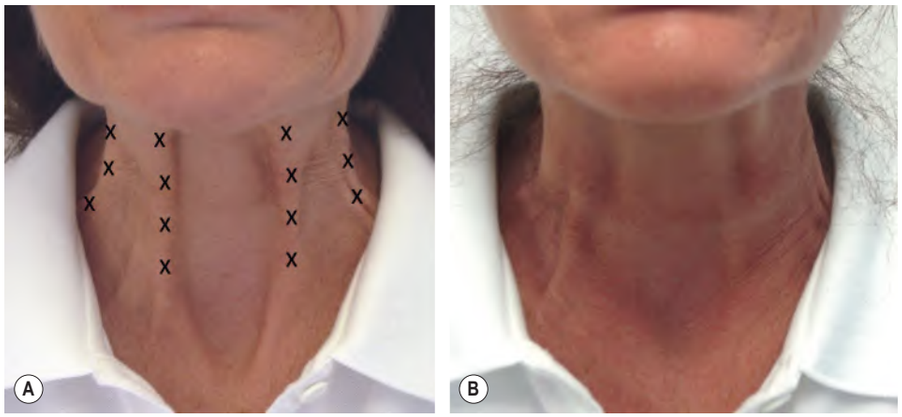

Fig. 159.20 Effect of BoNT-A injections on platysmal bands. Before (**A**) and after (**B**) treatment. Each band is injected in three sites at 1 to 1.5 cm intervals with 3–4 U of onaA per site.

now use BoNT-A injections as part of their standard laser resurfacing protocol. Likewise, combination treatment with BoNT-A and intense pulsed light (IPL) leads to greater global aesthetic benefits, with a reduction in fine lines and rhytides and improvement in skin tone, texture and erythema, compared to IPL alone[34]. Of note, BoNT-A injections delivered immediately into areas of moderate to severe edema due to laser resurfacing procedures or IPL can lead to increased and unwanted neurotoxin diffusion. Therefore, caution is recommended in this situation[34], especially since neurotoxin injections are often performed as a second procedure due to concern regarding neurotoxin inactivation by heat-producing lasers or light- and energy-based devices[34].

BoNT-A is also frequently used in combination with soft-tissue augmentation, where it prevents the distortion of the filler and prolongs the beneficial effects of tissue augmentation. Preceding the injection of filling agents by approximately 1 week, BoNT-A may work on several levels, including reducing the dynamic component of rhytide formation in newly remodeled skin and allowing more permanent eradication of rhytides[32]. Together, BoNT-A and fillers produce greater aesthetic improvements of longer duration than either modality alone[35].

MEDICAL USES OF BOTULINUM TOXIN TYPE A

Hyperhidrosis

Dramatically effective with minimal side effects, BoNT-A was approved for the treatment of axillary hyperhidrosis in Canada and the US in 2001 and 2004, respectively, and a high level of efficacy has been established in clinical trials for this indication (level A recommendation)[36,37]. Along with a decrease in perspiration lasting from 6 to 24 months, injections can improve quality of life and decrease body odor for up to 7 months[38,39].

Studies comparing onaA with aboA or incoA have shown similar levels of safety and efficacy[40,41], with a non-significant trend toward a more rapid onset of action with aboA[41]. RimaB, while effective, is associated with a greater amount of pain on injection and systemic adverse events (e.g. xerostomia, flu-like symptoms)[42].

Typically, 50–150 U of onaA per axilla are divided among 10–20 injection sites spaced 1.5–2 cm apart (Video 159.7). BoNT-A is injected intradermally or immediately subdermally. Injections are usually repeated at 6- to 12-month intervals, although, in the experience of the authors, most subjects are far below their pre-injection degree of hyperhidrosis when they present for reinjection. Alternatively, BoNT-A topically applied in large doses (200 U) has been shown to be safe and may prove to be an effective method for treating axillary hyperhidrosis[43].

The efficacy of BoNT-A in palmar hyperhidrosis is less assured (level B, probably effective), with a limited number of blinded, prospective trials[36,37]. Some consider BoNT-A only after failure of traditional treatment approaches, due to the necessity of anesthesia and the high doses required[38]. Typical doses of onaA for the palm range from 50–200 U distributed among 50–100 injection sites, including the distal wrist crease and the thenar and hypothenar eminences. Although studies show significant decreases in sweat production for 3–4 months (Fig. 159.21), most patients experience some degree of hand weakness that can last up to 2 weeks, with the thumb–index finger pinch significantly affected[44].

Fig. 159.21 Effect of BoNT-A injections on palmar hyperhidrosis. Only the right palm was treated as the right hand is the primary one used in social interactions. Small residual areas of sweating may be treated at a follow-up visit 2–4 weeks later.

Given that sweating, as well as friction, can exacerbate Hailey–Hailey disease, injections of BoNT-A into lesional skin can lead to clinical improvement. One approach is to utilize a total of 100 U, injecting 2 U into every cm^2 of involved skin.

Raynaud Phenomenon

BoNT-A is an increasingly utilized treatment for Raynaud phenomenon, defined as an exacerbated, transient vasospasm of the digital arteries, particularly in the hands, that is triggered by cold or emotional stress (see Ch. 43). Patients may experience three phases of skin discoloration: white (resulting from vasoconstriction and interruption of regional vascular flow), blue (cyanosis corresponding to blood de-oxygenation), and red (when reperfusion occurs). Pain and paresthesia due to sensory nerve ischemia may occur during an attack, and the condition may progress to ulcerations and gangrene[45].

BoNT-A injections appear to target both neural and vascular abnormalities responsible for the clinical manifestations of the syndrome, leading to a significant decrease in pain and improvements in color, mobility, blood flow and oxygen saturation, as well as healing of persistent digital ulcers[46–49]. BoNT-A is believed to work via two mechanisms: at the level of the vessel, promoting vasodilation due to the blockade of norepinephrine and acetylcholine release, and at the nerve, blocking receptors, and neurotransmitters that stimulate both pain (substance P, calcitonin gene-related peptide, and glutamate) and vasoconstriction[46].

Downloaded for Anonymous User (n/a) at Egyptian Knowledge Bank from ClinicalKey.com by Elsevier on March 10, 2024. For personal use only. No other uses without permission. Copyright ©2024. Elsevier Inc. All rights reserved.

Injection may be performed into the palmar region, wrists, and/or fingers. There is no consensus yet with regard to dose, dilution, or injection sites. The simplest technique involves 5 U onaA into the medial and lateral aspects of each finger at its base, using insulin syringes (BD Ultrafine II, 0.3 ml) for a total of 50 U onaA per hand. Some clinicians avoid injecting the thumb unless there is significant symptomatic involvement. Response can be perceived within days to a week with remarkable improvement of numbness and pain. Side effects, which are minimal and temporary, include local pain triggering a vasospastic attack.

These results warrant further investigation of clinical effect and optimal dosing with larger controlled trials.

Migraine

In 2011, the FDA approved onaA for chronic migraine prophylaxis. In addition to inhibiting release of acetylcholine from nerve endings (see Fig. 159.1), it can inhibit the release of glutamate, substance P, and calcitonin gene-related peptide (CGRP)[50]. The pathogenic role of the latter has led to the approval of several monoclonal antibodies (e.g. erenumab) and oral medications (e.g. ubrogepant) for migraine prophylaxis or treatment that target CGRP.

Typically, 100 U of onaA are distributed within the brow, temple and occipital regions, in addition to injections into any trigger sites. Historically, there have been mixed results, but a recent meta-analysis of randomized, double-blind, placebo-controlled trials reported a reduction in episode frequency and improved quality of life for up to three months after injections[50]. However, because the clinical effects on facial muscles are readily detectable, this has led to the criticism that trials are not truly blinded.

Depression

Research indicates that BoNT injections – and subsequent inability to frown – correlates with an improvement in symptoms of depression[51,52], suggesting that muscles of facial expression may play a role in mood regulation. A double-blind, randomized, placebo-controlled trial of 30 patients with major depression found that scores on the Hamilton Depression Rating Scale, Beck Depression Inventory, and Clinical Global Impressions Scale decreased by an average of 47% after one treatment with BoNT-A in the glabella, compared to a 9% reduction in patients who received saline[53]. Results were maintained over the 16-week follow-up period. In a second randomized, placebo-controlled trial, half of the patients with major depression responded to BoNT-A injections to the corrugator and procerus muscles, with an ~50% reduction in scores on the Montgomery–Åsberg Depression Rating Scale[52]. Only 15% of patients who received placebo reported such improvement.

COMPLICATIONS

BoNT-A occasionally affects non-targeted muscles or glandular tissue in the areas surrounding the injection, which can result in effects such as eyelid ptosis (Fig. 159.22), lower eyelid laxity, epiphora (excessive tearing), diplopia, brow ptosis, decreased strength of eye closure, dry eye, mouth incompetence, difficulties in speech, and the inability to whistle. Use of both careful injection technique to target the toxin to the appropriate muscles and concentrated low doses to limit its diffusion to non-targeted muscles or glands are recommended to prevent the occurrence of these adverse effects[53]. In general, a higher concentration allows for more accurate placement, greater duration of effect and fewer side effects, since lower concentrations may encourage the spread of toxin. Of note, there is an area of denervation associated with each point of injection of about 1–1.5 cm (diameter, 2–3 cm) that is due to toxin spread.

A quizzical or "cockeyed" appearance can occur in the brow when the lateral fibers of the frontalis muscle have not been injected adequately and these untreated lateral fibers pull upward on the brow (Fig. 159.23). Brow ptosis may last upwards of 3 months, while upper eyelid ptosis can persist for 2–12 weeks. When upper eyelid ptosis occurs, options include: (1) thrice daily 0.5% apraclonidine eyedrops, an α_2-adrenergic agonist used for glaucoma, which leads to contraction of the Müller muscle and a 1–2 mm elevation of the upper eyelid[54]; (2) oral pyridostigmine bromide (60 mg 3–4 times daily), an anticholinesterase drug used for myasthenia gravis that inhibits acetylcholine breakdown, whose side effects include hypersalivation, blurred vision, muscle cramps, vomiting, and diarrhea[54]; and (3) precise injections of 0.5–1 U of BoNT-A into the subdermal plane just above the eyelash line at the extreme medial and lateral aspects of the upper eyelid, thereby reducing the strength of the orbicularis oculi muscle and allowing the Müller muscle and the levator muscle to become less opposed[55].

Bruising, diplopia, ectropion, a drooping lateral lower eyelid, and an asymmetric smile (caused by the spread of toxin to the zygomaticus major) are also reported complications of BoNT-A injections in the periorbital area. Transient local bruising, ptosis, dry eyes, diplopia, and facial droop can occur with injections into the cheek.

Fig. 159.23 Cockeyed eyebrow. Untreated lateral fibers of the frontalis muscle pull upward on the lateral brow. The result is a quizzical appearance.

Fig. 159.22 Blepharoptosis. Diffusion of toxin into the levator of the upper eyelid resulted in eyelid ptosis (**A**) with partial recovery after 3 weeks (**B**) and complete recovery after 5 weeks (**C**). See text for therapeutic options.

Downloaded for Anonymous User (n/a) at Egyptian Knowledge Bank from ClinicalKey.com by Elsevier on March 10, 2024. For personal use only. No other uses without permission. Copyright ©2024. Elsevier Inc. All rights reserved.

Complications of the lower face involve effects on muscle function and facial expression, usually due to use of BoNT-A in large doses. Injections placed too close to the mouth, injection into the mental fold, and interaction with the orbicularis oris muscle can all result in a flaccid cheek, incompetent mouth, or asymmetric smile. Large doses (>100 U) of onaA in the platysma have resulted in reports of dysphagia and weakness of the neck flexors.

Although one of the greatest concerns associated with the use of BoNT-A is the formation of neutralizing antibodies leading to non-response of subsequent injections, the overall risk is actually low (<1%) when BoNT-A is used at recommended doses for cosmetic applications. Of note, the protein content in current lots of BoNT-A is significantly lower than in previous batches and has been shown to be less antigenic than the original product. Although antibody formation has occurred with current lots of BoNT-A[56], it is usually associated with the use of large doses for therapeutic, rather than cosmetic, purposes[57]. The lack of complexing proteins in incoA reduces the antigenicity[56] but does not appear to eliminate it entirely[58]. Injecting the lowest effective doses, with the longest feasible intervals between injections, minimizes the potential for immunogenicity.

Allergic reactions to BoNT-A are rare but have been described in the literature. Additional reactions include serious or non-serious cutaneous eruptions[59] as well as granulomas[60]. After large doses for therapeutic purposes, anaphylactic reactions and severe respiratory failure have occurred[61,62].

SAFETY

No long-term adverse effects have been reported, and no systemic safety problems have been associated with FDA-approved uses of BoNT. A review of the long-term safety of BoNT-A for cosmetic purposes revealed no serious adverse events (AEs) in over 850 treatment sessions for up to 9 years[63]. An interim analysis of 768 patients enrolled in phase 3 clinical trials, who received up to six treatments of aboA, found that multiple treatments over 17 months were well tolerated[64]. A large-scale, comprehensive phase III program of onaA for crow's feet and glabellar rhytides comprising three trials, 684 patients, and up to four treatment cycles found no serious treatment-related AEs, evidence of distant spread of the toxin, or immunogenicity over a 12-month period[65]. Side effects were mostly mild and included hematoma, headache, and injection-site hemorrhage. Treating both the crow's feet region and glabellar rhytides at the same time did not result in an increased incidence of AEs, and side effects appeared to decline with repeated treatments.

However, the risk of serious complications increases with higher doses: in an analysis of 1031 AE reports submitted to the FDA, 407 occurred with higher therapeutic doses, including 28 deaths and other serious cardiovascular complications[59]. The FDA could not determine a causal relationship between the fatalities and BoNT-A injections, especially since 26 patients who died had underlying cardiovascular diseases with an elevated mortality risk. Notably, no deaths or cardiovascular complications were associated with cosmetic doses. Similarly, another investigation of 658 FDA-submitted AEs, which included 180 cases of aspiration, dysphagia and/or pneumonia and 16 deaths, involved only therapeutic doses in already compromised individuals[66]. As a result, the FDA requested safety label changes with black box warnings and a *r*isk *e*valuation and *m*itigation *s*trategy (REMS), including a consumer guide outlining the risks associated with treatment, for all BoNT products[67].

FUTURE TRENDS

The use of BoNT continues to evolve, with new applications that deepen our understanding of clinical effect and mechanism of action. There have been anecdotal reports of tighter, smoother skin after BoNT-A injections, as well as a lower incidence of acne[68]. Current research indicates that BoNT-A acts on the biological behavior of fibroblasts, including reducing production of matrix metalloproteinases (MMPs), responsible for the slow degradation of type I collagen, and stimulating the production of procollagen I. Collagen production and degradation has been investigated *in vitro* by measuring procollagen type I carboxy-terminal peptide (PIP) and MMPs, respectively. Levels of PIP increased significantly when fibroblasts were grown in the presence of BoNT, with upregulation of type I collagen and a decrease in MMPs[69]. In an *in vivo* investigation of the effects of BoNT on photodamaged skin, mice were pretreated with BoNT-A and subsequently irradiated with ultraviolet B light[70]. Compared to control mice, those injected with BoNT-A had significantly decreased secretion of inflammatory cytokines associated with photodamage and postinflammatory hyperpigmentation.

Intradermal injection of BoNT-A has been used with success to treat oily skin and enlarged pores. When the T-zone (forehead and nose) was injected in a series of 20 patients, 17 reported an improvement in skin oiliness[71]. Significantly lower sebum production was noted in 25 patients treated with 3 to 5 U of aboA in each of ten injection sites across the forehead, as measured by a sebometer[72]. The authors speculated that blockade of local acetylcholine receptors in the pilosebaceous unit with BoNT-A could result in altered rates of sebum production.

SUMMARY

BoNT-A remains the treatment of choice for smoothing hyperkinetic lines in the face and neck, creating a more pleasant and youthful appearance. Alone or in combination with surgery, soft-tissue augmentation, or ablative and non-ablative laser resurfacing, BoNT-A treatment is both an art and a science, with its use in facial sculpting and enhancing, along with dermatologic correction. Intramuscular injections of BoNT-A have also become first-line therapeutic options for a number of disorders characterized by muscular hyperactivity, such as strabismus, blepharospasm, hemifacial spasm, and cervical dystonia. In addition, the ability of BoNT to block acetylcholine release and other neurotransmitters from autonomic nerve endings innervating glandular tissue or smooth muscle has led to its use for hyperhidrosis, migraine prophylaxis, and Raynaud phenomenon. Easy to use, minimally invasive, and well tolerated, BoNT carries an impressive safety record, and there is no doubt its number of indications will continue to grow.

Additional figures available in our eBook (see inside front cover for access code).

REFERENCES

1. Jankovic J, Hallett M, eds. *Therapy with Botulinum Toxin*. New York: Marcel Dekker; 1994.
2. Hexsel D, Brum C, do Prado DZ, et al. Field effect of two commercial preparations of botulinum toxin type A: a prospective, double-blind, randomized clinical trial. *J Am Acad Dermatol*. 2012;67:226–232.
3. Kerscher M, Roll S, Becker A, Wigger-Alberti W. Comparison of the spread of three botulinum toxin type A preparations. *Arch Dermatol Res*. 2012;304:155–161.
4. Hexsel D, Dal'Forno T, Hexsel C, et al. A randomized pilot study comparing the action halos of two commercial preparations of botulinum toxin type A. *Dermatol Surg*. 2008;34:52–59.
5. Wilson AJ, Chang B, Taglienti AJ, et al. A quantitative analysis of onabotulinumtoxinA, abobotulinumtoxinA, and incobotulinumtoxinA: a randomized, double-blind, prospective clinical trial of comparative dynamic strain reduction. *Plast Reconstr Surg*. 2016;137:1424–1433.
6. Thomas AJ, Larson MO, Braden S, et al. Effect of 3 commercially available botulinum toxin neuromodulators on facial synkinesis: a randomized clinical trial. *JAMA Facial Plast Surg*. 2018;20:141–147.
7. Monheit G, Pickett A. Basic science: abobotulinum toxin A. In: Carruthers A, Carruthers J, Dover JS, Alam M, eds. *Procedures in Cosmetic Dermatology: Botulinum Toxin. 3rd ed. New York: Saunders Elsevier*; 201326–34.
8. Nettar KD, Yu KC, Bapna S, et al. An internally controlled, double-blind comparison of the efficacy of onabotulinumtoxinA and abobotulinumtoxinA. *Arch Facial Plast Surg*. 2011;13:380–386.
9. Karsai S, Raulin C. Current evidence on the unit equivalence of different botulinumneurotoxinA formulations and recommendations for clinical practice in dermatology. *Dermatol Surg*. 2009;35:1–8.
10. Sattler G, Callander MJ, Grablowitz D, et al. Noninferiority of incobotulinumtoxinA, free from complexing proteins, compared with another botulinum toxin type A in the treatment of glabellar frown lines. *Dermatol Surg*. 2010;36:2146–2154.
11. Carruthers A, Carruthers J, Coleman 3rd WP, et al. Multicenter, randomized, phase III study of a single dose of incobotulinumtoxinA, free from complexing proteins, in the treatment of glabellar frown lines. *Dermatol Surg*. 2013;39:551–558.
12. Prager W, Bee EK, Havermann I, Zschocke I. Onset, longevity, and patient satisfaction with incobotulinumtoxinA for the treatment of glabellar frown lines: a single-arm, prospective clinical study. *Clin Interv Aging*. 2013;8:449–456.
13. Frevert J, Sattler G. Basic science: xeomin. In: Carruthers A, Carruthers J, Dover JS, Alam M, eds. *Procedures in Cosmetic Dermatology: Botulinum Toxin*. 3rd ed. New York: Saunders Elsevier; 2013:35–42.
14. Carli L, Montecucco C, Rossetto O. Assay of diffusion of different botulinum neurotoxin type A formulations injected in the mouse leg. *Muscle Nerve*. 2009;40:374–380.

Downloaded for Anonymous User (n/a) at Egyptian Knowledge Bank from ClinicalKey.com by Elsevier on March 10, 2024. For personal use only. No other uses without permission. Copyright ©2024. Elsevier Inc. All rights reserved.

15. Rzany BJ, Ascher B, Avelar RL, et al. A multicenter, randomized, double-blind, placebo-controlled, single-dose, phase III, non-inferiority study comparing prabotulinumtoxinA and onabotulinumtoxinA for the treatment of moderate to severe glabellar lines in adult patients. *Aesthet Surg J*. 2020;40:413–429.
16. Won CH, Lee HM, Lee WS, et al. Efficacy and safety of a novel botulinum toxin type A product for the treatment of moderate to severe glabellar lines: a randomized, double-blind, active-controlled multicenter study. *Dermatol Surg*. 2013;39:171–178.
17. Matarasso SL. Comparison of botulinum toxin types A and B: a bilateral and double-blind randomized evaluation in the treatment of canthal rhytides. *Dermatol Surg*. 2003;29:7–13.
18. Carruthers A, Carruthers J, Flynn TC, Leong MS. Dose-finding, safety, and tolerability study of botulinum toxin type B for the treatment of hyperfunctional glabellar lines. *Dermatol Surg*. 2007;33:S60–S68.
19. Bar-Ilan E, Koren A, Shehadeh W, et al. An enhanced transcutaneous delivery of botulinum toxin for the treatment of Hailey-Hailey disease. *Dermatol Ther*. 2020;33:e13184.
20. Friedman O, Koren A, Niv R, et al. The toxic edge: a novel treatment for refractory erythema and flushing of rosacea. *Lasers Surg Med*. 2019;51:325–331.
21. Junsuwan N, Manuskiatti W, Phothong W, Wanitphakdeedecha R. Fractional CO_2 laser-assisted botulinum toxin type A delivery for the treatment of primary palmar hyperhidrosis. *Lasers Med Sci*. 2021;36:233–236.
22. Waugh JM, Glogau RG. Topical neurotoxin. In: Carruthers A, Carruthers J, Dover JS, Alam M, eds. *Procedures in Cosmetic Dermatology: Botulinum Toxin*. 3rd ed. New York: Saunders Elsevier; 2013:67–71.
23. Brandt F, O'Connell C, Cazzaniga A, Waugh JM. Efficacy and safety evaluation of a novel botulinum toxin topical gel for the treatment of moderate to severe lateral canthal lines. *Dermatol Surg*. 2010;36(Suppl. 4):2111–2118.
24. Glogau R, Blitzer A, Brandt F, et al. Results of a randomized, double-blind, placebo-controlled study to evaluate the efficacy and safety of a botulinum toxin type A topical gel for the treatment of moderate-to-severe lateral canthal lines. *J Drugs Dermatol*. 2012;11:38–45.
25. Clinical trial to evaluate ANT-1207 in participants with primary axillary hyperhidrosis. <https://clinicaltrials.gov/ct2/show/NCT02479139>
26. Bertucci V, Solish N, Kaufman-Janette J, et al. DaxibotulinumtoxinA for injection has a prolonged duration of response in the treatment of glabellar lines: pooled data from two multicenter, randomized, double-blind, placebo-controlled, phase 3 studies (SAKURA 1 and SAKURA 2). *J Am Acad Dermatol*. 2020;82:838–845.
27. Carruthers A, Carruthers J. Eyebrow height after botulinum toxin type A to the glabella. *Dermatol Surg*. 2007;33:S26–S31.
28. Flynn TC, Carruthers JA, Carruthers JA. Botulinum-A toxin treatment of the lower eyelid improves infraorbital rhytides and widens the eye. *Dermatol Surg*. 2001;27:703–708.
29. deMaio M. Facial asymmetries. In: deMaio M, Rzany B, eds. *Botulinum Toxin in Aesthetic Medicine*. Berlin: Springer-Verlag; 2007:93–101.
30. Liew S, Dart A. Nonsurgical reshaping of the lower face. *Aesthet Surg J*. 2008;28:251–257.
31. Carruthers J, Carruthers A. Practical cosmetic Botox techniques. *J Cutan Med Surg*. 1999;3(Suppl. 4):S49–S52.
32. Fagien S. Botox for the treatment of dynamic and hyperkinetic facial lines and furrows: adjunctive use in facial aesthetic surgery. *Plast Reconstr Surg*. 2003;112:40S–52S.
33. Zimbler M, Undavia S. Update on the effect of botulinum toxin pretreatment on laser resurfacing results. *Arch Facial Plast Surg*. 2012;14:156–158.
34. Giordano CN, Matarasso SL, Ozog DM. Injectable and topical neurotoxins in dermatology: indications, adverse events, and controversies. *J Am Acad Dermatol*. 2017;76:1027–1042.
35. Beer KR. Combined treatment for skin rejuvenation and soft-tissue augmentation of the aging face. *J Drugs Dermatol*. 2011;10:125–132.
36. Naumann M, Dressler D, Hallett M, et al. Evidence-based review and assessment of botulinum neurotoxin for the treatment of secretory disorders. *Toxicon*. 2013;67:141–152.
37. Lakraj AA, Moghimi N, Jabbari B. Hyperhidrosis: anatomy, pathophysiology and treatment with emphasis on the role of botulinum toxins. *Toxins (Basel)*. 52013821–840.
38. Nawrocki S, Cha J. The etiology, diagnosis, and management of hyperhidrosis: a comprehensive review: therapeutic options. *J Am Acad Dermatol*. 2019;81:669–680.
39. Heckmann M, Teichmann B, Pause BM, Plewig G. Amelioration of body odor after intracutaneous axillary injection of botulinum toxin A. *Arch Dermatol*. 2003;139:57–59.
40. Talarico-Filho S, Mendonça DO, Nascimento M, et al. A double-blind, randomized, comparative study of two type A botulinum toxins in the treatment of primary axillary hyperhidrosis. *Dermatol Surg*. 2007;33:S44–S50.
41. El Kahky HM, Diab HM, Aly DG, Farag NM. Efficacy of onabotulinum toxin A (Botox) versus abobotulinum toxin A (Dysport) using a conversion factor (1:2.5) in treatment of primary palmar hyperhidrosis. *Dermatol Res Pract*. 2013:686329.
42. Glaser DA, Mattox AR. Focal axillary hyperhidrosis. In: Carruthers A, Carruthers J, Dover JS, Alam M, eds. *Procedures in Cosmetic Dermatology: Botulinum Toxin*. 3rd ed. New York: Saunders Elsevier; 2013:160–168.
43. Lueangarun S, Sermsilp C, Tempark T. Topical botulinum toxin type A liposomal cream for primary axillary hyperhidrosis: a double-blind, randomized, split-site, vehicle-controlled study. *Dermatol Surg*. 2018;44:1094–1101.
44. Mariwalla K, Solish N. Palmo-plantar hyperhidrosis. In: Carruthers A, Carruthers J, Dover JS, Alam M, eds. *Procedures in Cosmetic Dermatology: Botulinum Toxin*. 3rd ed. New York: Saunders Elsevier; 2013:169–174.
45. Levien TL. Advances in the treatment of Raynaud's phenomenon. *Vasc Health Risk Manag*. 2010;6:167–177.
46. Kossintseva I, Barankin B. Improvement in both Raynaud disease and hyperhidrosis in response to botulinum toxin type A treatment. *J Cutan Med Surg*. 2008;12:189–193.
47. Fregene A, Ditmars D, Siddiqui A. Botulinum toxin type A: a treatment option for digital ischemia in patients with Raynaud's phenomenon. *J Hand Surg Am*. 2009;34:446–452.
48. Neumeister MW. Botulinum toxin type A in the treatment of Raynaud's phenomenon. *J Hand Surg Am*. 2010;35:2085–2092.
49. Smith L, Polsky D, Franks Jr. AG. Botulinum toxin-A for the treatment of Raynaud syndrome. *Arch Dermatol*. 2012;148:426–428.
50. Bruloy E, Sinna R, Grolleau JL, et al. Botulinum toxin versus placebo: a meta-analysis of prophylactic treatment for migraine. *Plast Reconstr Surg*. 2019;143:239–250.
51. Wollmer MA, de Boer C, Kalak N, et al. Facing depression with botulinum toxin: a randomized controlled trial. *J Psychiatr Res*. 2012;46:574–581.
52. Finzi E, Rosenthal NE. Treatment of depression with onabotulinumtoxinA: a randomized, double-blind, placebo controlled trial. *J Psych Res*. 2014;52:1–6.
53. Klein AW. Complications, adverse reactions, and insights with the use of botulinum toxin. *Dermatol Surg*. 2003;29:549–556.
54. Karami M, Taheri A, Mansoori P. Treatment of botulinum toxin-induced eyelid ptosis with anticholinesterases. *Dermatol Surg*. 2007;33:1392–1395.
55. Fagien S. Temporary management of upper lid ptosis, lid malposition, and eyelid fissure asymmetry with botulinum toxin type A. *Plast Recons Surg*. 2004;114:1892–1902.
56. Hefter H, Hartmann C, Kahlen U, et al. Prospective analysis of neutralising antibody titres in secondary non-responders under continuous treatment with a botulinumtoxin type A preparation free of complexing proteins–a single cohort 4-year follow-up study. *Br Med J Open*. 2012:2 pii:e000646.
57. Mejia NI, Vuong KD, Jankovic J. Long-term botulinum toxin efficacy, safety, and immunogenicity. *Mov Disord*. 2005;20:592–597.
58. Dressler D. IncobotulinumtoxinA (Xeomin®) can produce antibody-induced therapy failure in a patient pretreated with abobotulinumtoxinA (Dysport®). *J Neural Transm*. 2014;121:769–771.
59. Coté TR, Mohan AK, Polder JA, et al. Botulinum toxin type A injections: adverse events reported to the US Food and Drug Administration in therapeutic and cosmetic cases. *J Am Acad Dermatol*. 2005;53:407–415.
60. Ahbib S, Lachapelle JM, Marot L. Sarcoidal granulomas following injections of botulinum toxin A (Botox) for corrections of wrinkles. *Ann Dermatol Venereol*. 2006;133:43–45.
61. LeWitt PA, Trosch RM. Idiosyncratic adverse reactions to intramuscular botulinum toxin type A injection. *Mov Disord*. 1997;12:1064–1067.
62. Li M, Goldberger BA, Hopkins C. Fatal case of BOTOX-related anaphylaxis? *J Forensic Sci*. 2005;50:169–172.
63. Carruthers J, Carruthers A. Complications of botulinum toxin type A. *Facial Plast Surg Clin North Am*. 2007;15:51–54.
64. Monheit GD, Cohen JL. J Long-term safety of repeated administrations of a new formulation of botulinum toxin type A in the treatment of glabellar lines: interim analysis from an open-label extension study. *J Am Acad Dermatol*. 2009;61:421–425.
65. Carruthers J, Rivkin A, Donofrio L, et al. A multicenter, randomized, double-blind, placebo-controlled study to evaluate the efficacy and safety of repeated onabotulinumtoxinA treatments in subjects with crow's feet lines and glabellar lines. *Dermatol Surg*. 2015;41:702–711.
66. US Food and Drug Administration. Early communication about an ongoing safety review Botox and Botox Cosmetic (botulinum toxin type A) and Myobloc (botulinum toxin type B). *Plast Surg Nurs*. 2008;28:150–151.
67. Kuehn BM. FDA requires black box warnings on labeling for botulinum toxin products. *JAMA*. 2009;301:2316.
68. Brin MF, Boodhoo TI, Pogoda JM, et al. Safety and tolerability of onabotulinumtoxinA in the treatment of facial lines: a meta-analysis of individual patient data from global clinical registration studies in 1678 participants. *J Am Acad Dermatol*. 2009;61:961–970.
69. Oh SH, Lee Y, Seo YJ, et al. The potential effect of botulinum toxin type A on human dermal fibroblasts: an in vitro study. *Dermatol Surg*. 2012;38:1689–1694.
70. Jung JA, Kim BJ, Kim MS, et al. Protective effect of botulinum toxin against ultraviolet-induced skin pigmentation. *Plast Reconstr Surg*. 2019;144:347–356.
71. Shah AR. Use of intradermal botulinum toxin to reduce sebum production and facial pore size. *J Drugs Dermatol*. 2008;7:847–850.
72. Rose AE, Goldberg DJ. Safety and efficacy of intradermal injection of botulinum toxin for the treatment of oily skin. *Dermatol Surg*. 2013;39:443–448.

Downloaded for Anonymous User (n/a) at Egyptian Knowledge Bank from ClinicalKey.com by Elsevier on March 10, 2024. For personal use only. No other uses without permission. Copyright ©2024. Elsevier Inc. All rights reserved.

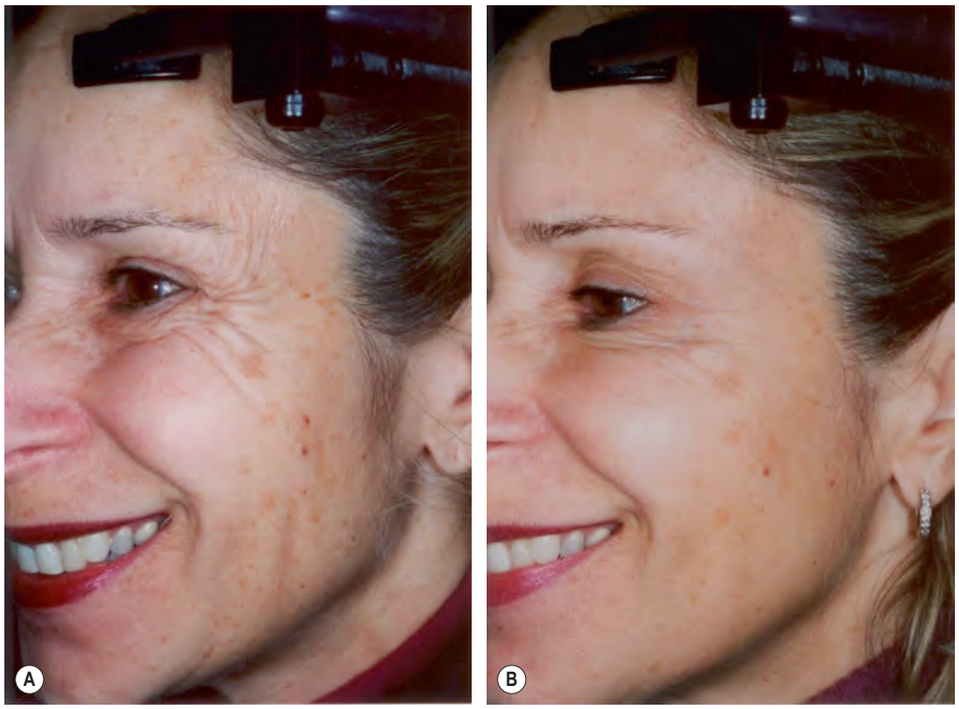

eFig. 159.1 Crow's feet. Subject with crow's feet before (**A**) and 3 weeks after BoNT-A treatment (**B**).

eFig. 159.2 Partial right frontalis paralysis after surgery for removal of a forehead osteoma. Before (**A**, **B**) and 2 weeks after glabellar (**C**, **D**) lateral orbicularis and left frontalis injections.

Downloaded for Anonymous User (n/a) at Egyptian Knowledge Bank from ClinicalKey.com by Elsevier on March 10, 2024. For personal use only. No other uses without permission. Copyright ©2024. Elsevier Inc. All rights reserved.

eFig. 159.3 Mouth frown. The subject before (**A**) and after BoNT-A treatment (**B**) of the depressor anguli oris muscle.

eFig. 159.4 Effect of BoNT-A injections for mouth frown. Before (**A**) and after (**B**) BoNT-A treatment. The authors typically inject 2–3 U of onaA into the posterior aspect of the depressor anguli oris muscle and 3 U into each insertion of the mentalis muscle.

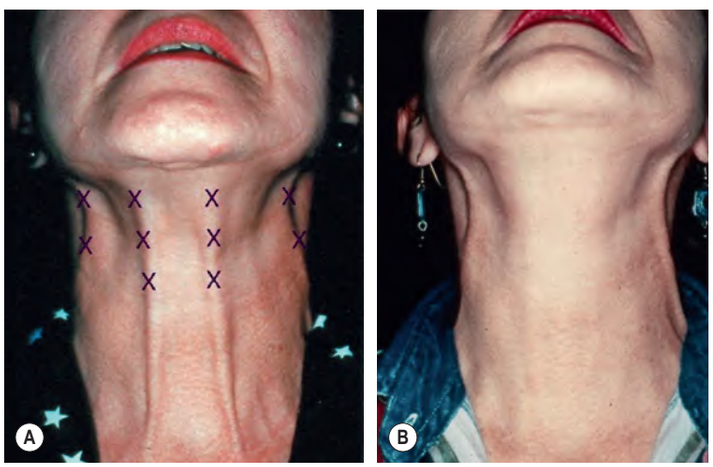

eFig. 159.5 Injection sites for platysmal bands. Before (**A**) and after treatment (**B**). Each band is injected in three sites at 1 to 1.5 cm intervals with 3–4 U of BoNT-A (onabotulinumtoxinA) per site. *Courtesy M. Carney, MD.*

eFig. 159.6 Injection sites for horizontal necklace lines. Aliquots of 1 to 2 U of BoNT-A (onabotulinumtoxinA) are injected into the deep intradermal plane at 2 to 3 cm intervals.

Downloaded for Anonymous User (n/a) at Egyptian Knowledge Bank from ClinicalKey.com by Elsevier on March 10, 2024. For personal use only. No other uses without permission. Copyright ©2024. Elsevier Inc. All rights reserved.

eFig. 159.7 Intense pulsed light plus BoNT-A injections. Subject before (**A**) and after combined therapy (**B**).

eFig. 159.8 Injection sites for palmar hyperhidrosis. The authors inject 100 to 150 U BoNT-A (onabotulinumtoxinA) per hand (depending on size) in approximately 100 injection sites.

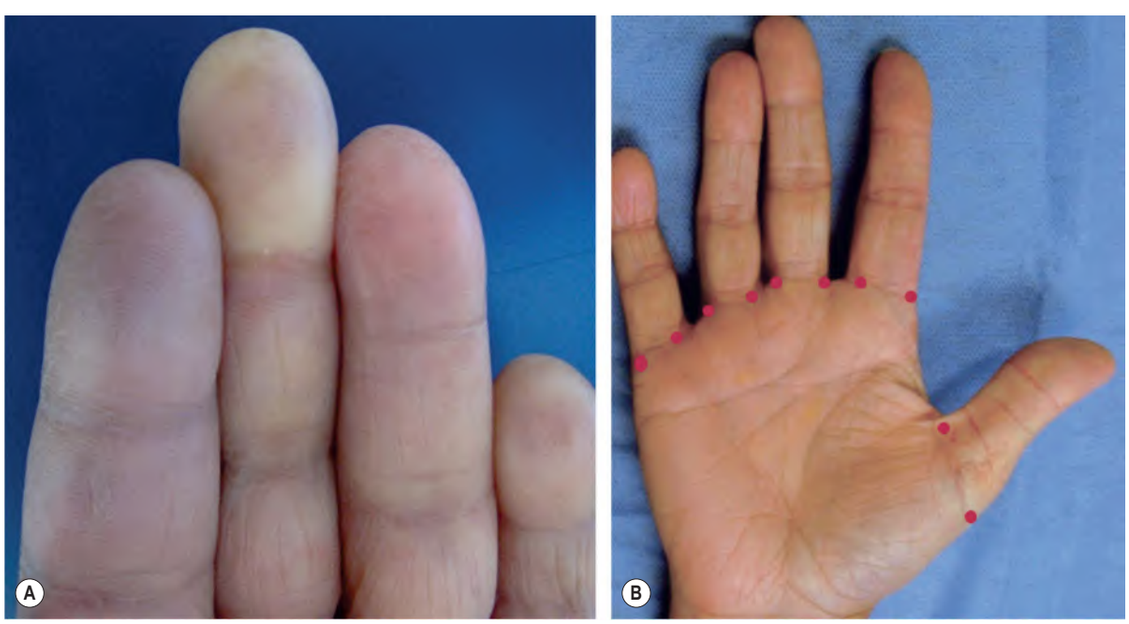

eFig. 159.9 Raynaud phenomenon. A Pallor of fingers due to vasoconstriction and interruption of regional vascular flow as well as blue-colored cyanosis corresponding to blood de-oxygenation. **B** Injection of BoNT-A into the bases of the fingers restores normal circulation. Some clinicians do not inject the thumb unless it has significant disease.

Downloaded for Anonymous User (n/a) at Egyptian Knowledge Bank from ClinicalKey.com by Elsevier on March 10, 2024. For personal use only. No other uses without permission. Copyright ©2024. Elsevier Inc. All rights reserved.

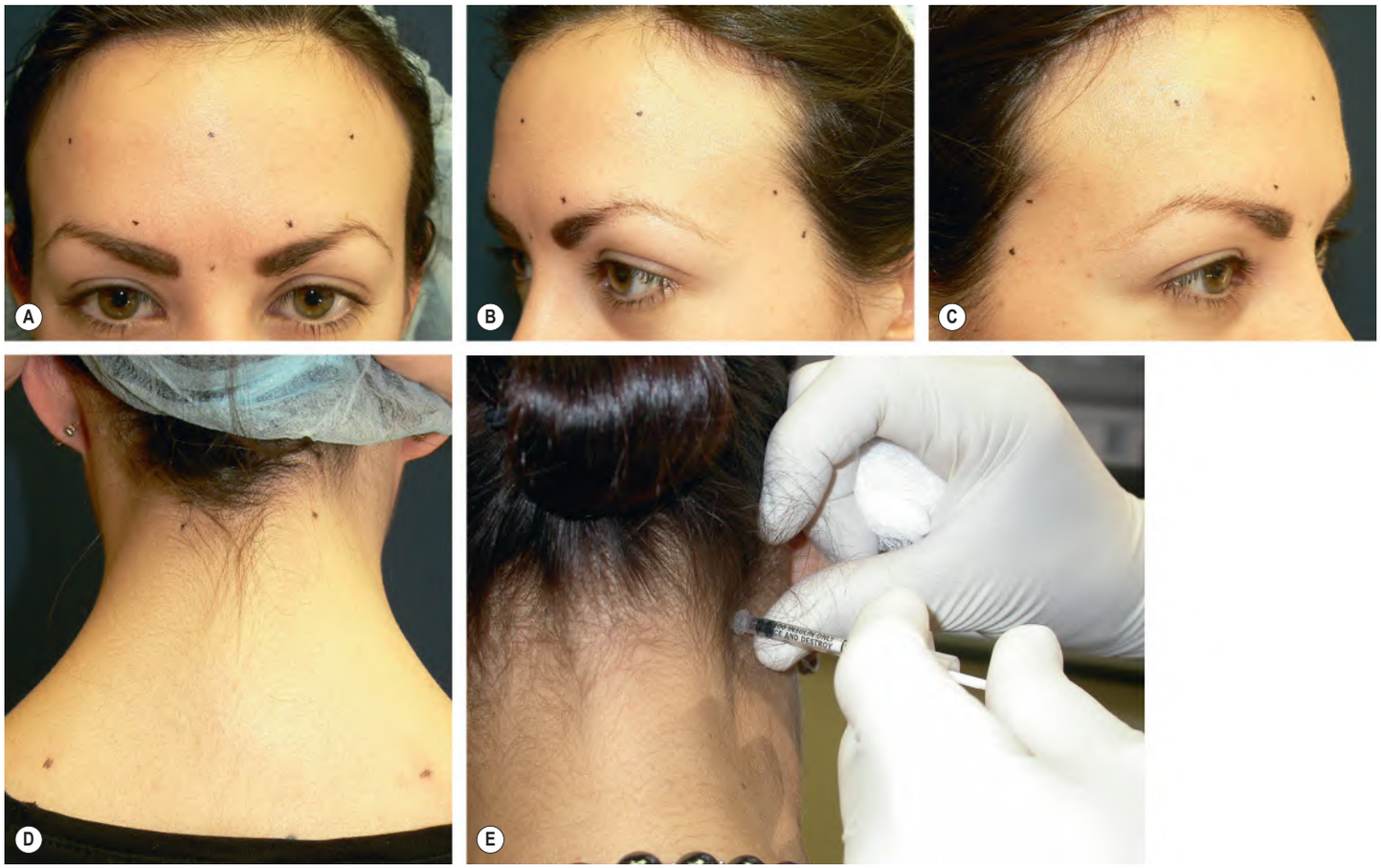

eFig. 159.10 A–E Injection sites for migraine. The authors usually inject 100 U BoNT-A (onaA) distributed between the brow, temples, and occipital areas.

Downloaded for Anonymous User (n/a) at Egyptian Knowledge Bank from ClinicalKey.com by Elsevier on March 10, 2024. For personal use only. No other uses without permission. Copyright ©2024. Elsevier Inc. All rights reserved.